Total Orthopedics
and Sports Medicine

SHOULDER INSTABILITY

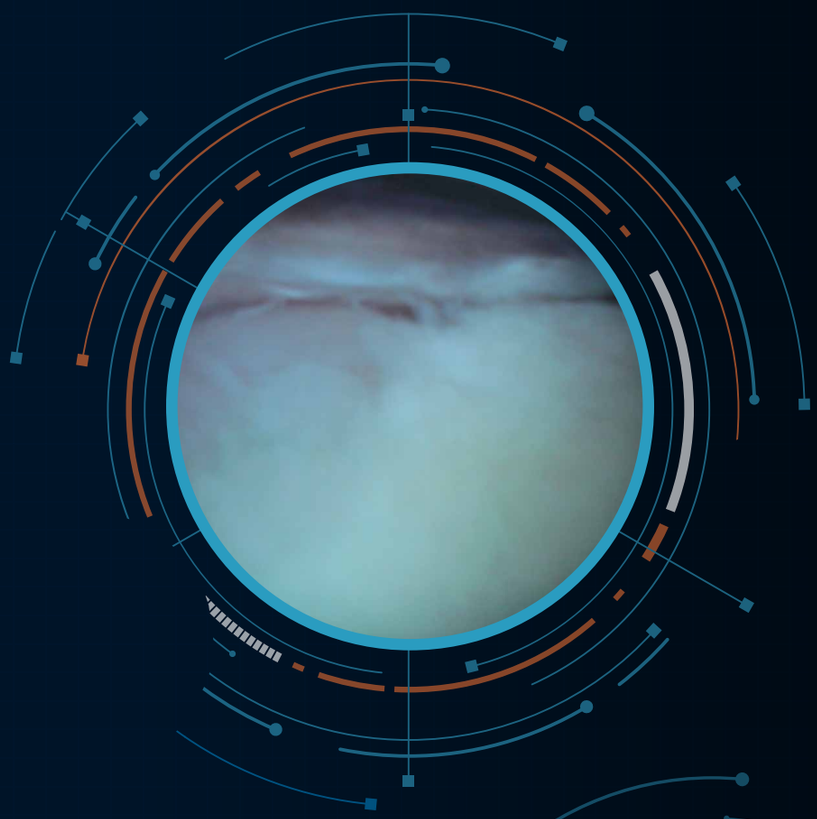

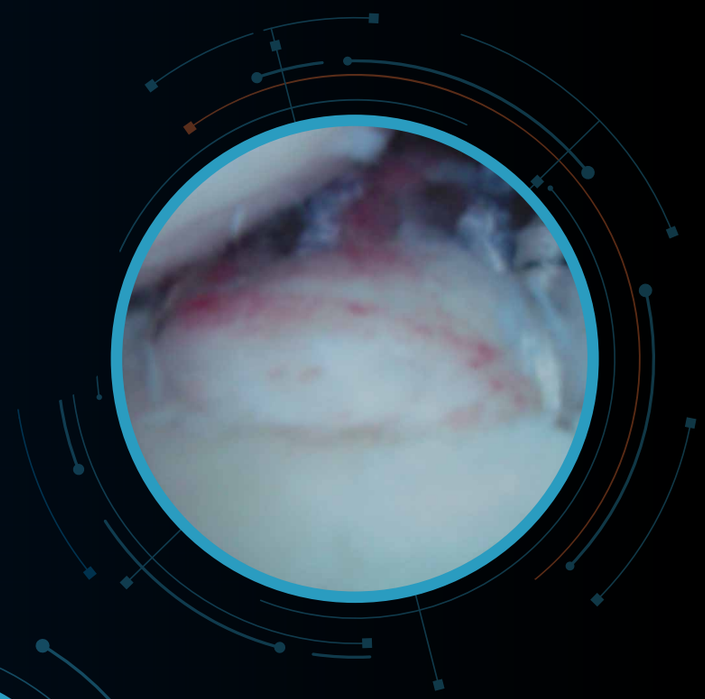



CAUSES OF INSTABILITY

Traumatic Instability

Specific injury causes instability

Usually associated with dislocation but may be only subluxation

Unidirectional *(dislocates in only one direction)*

Associated with Bankart Lesion *(Torn Labrum)*

Treated with Surgery especially when recurrent

Non-traumatic Instability

Nonspecific injury or overuse

Can be multidirectional *(dislocates out the front and back of the shoulder)*

No specific injury visualized on MRI or arthroscopy

Treated with physical therapy

Suture capsulorrhaphy *(tightening of capsule arthroscopically)* reserved for patients who fail physical therapy

TRAUMATIC INSTABILITY

ANTERIOR INSTABILITY

Associated with fall on shoulder or arm forced in abducted externally rotated position

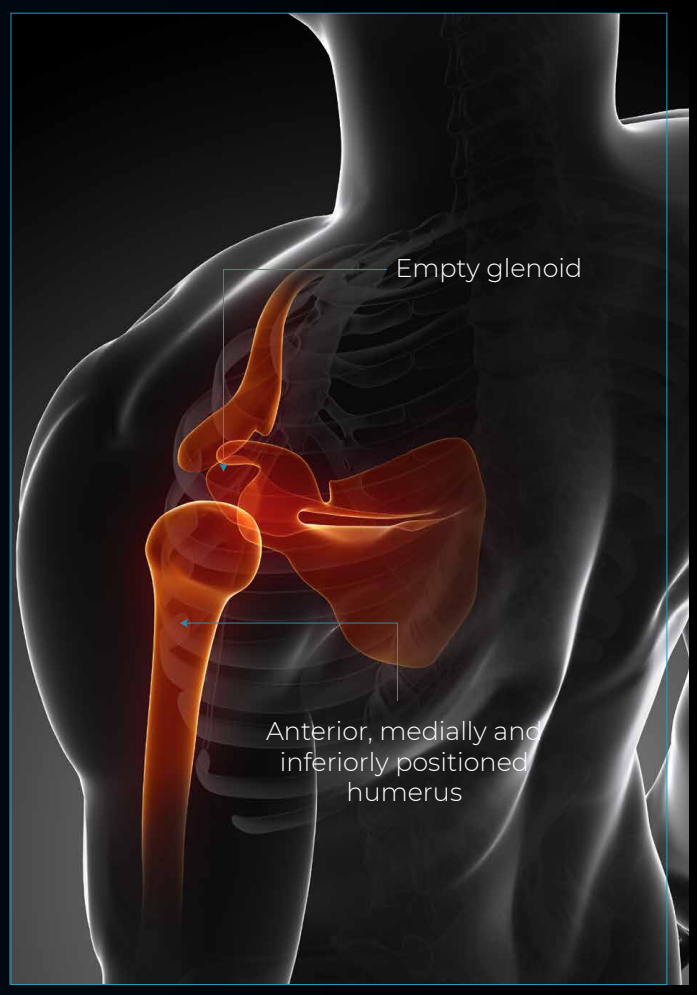

- Can cause **Bankart lesion**, **Hill-Sachs impaction fracture**, **glenoid fracture** *(Bony Bankart)*, and **glenoid impaction injury**

- Associated injuries can be **neurologic stretch injury**, **rotator cuff tear** (in patients over 40), and **osteoarthritis** from recurrent instability

Normal

Bankart Lesion

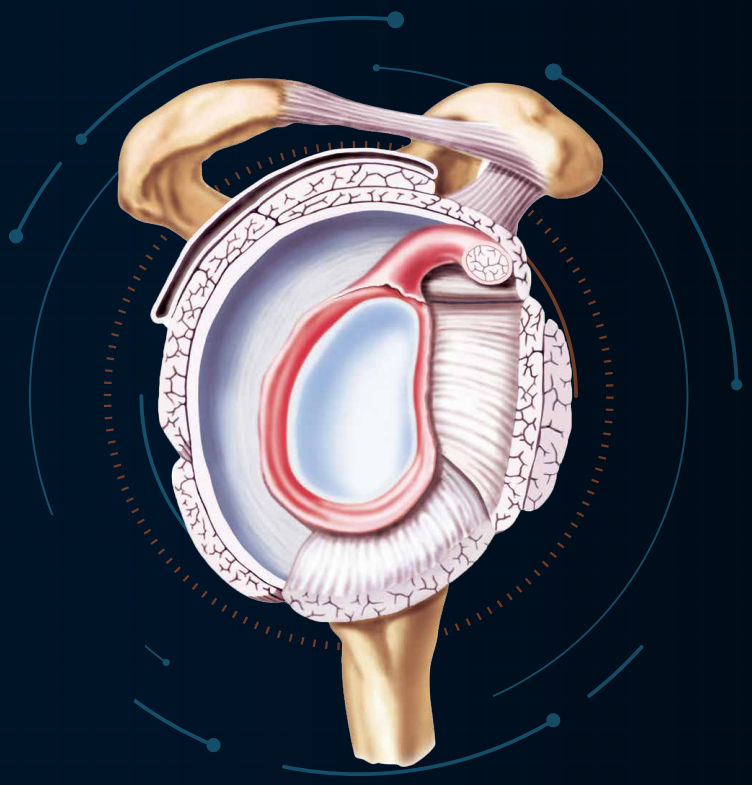

Normal

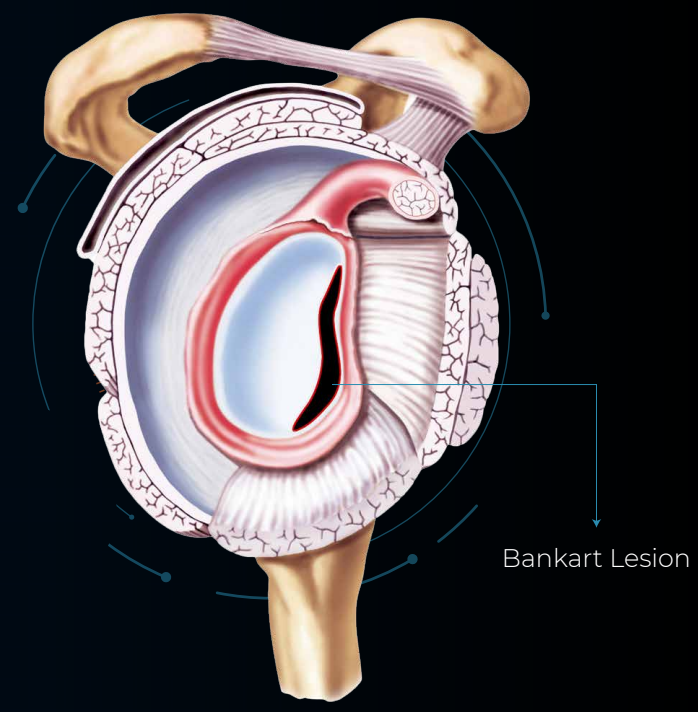

Hill-Sachs Lesion

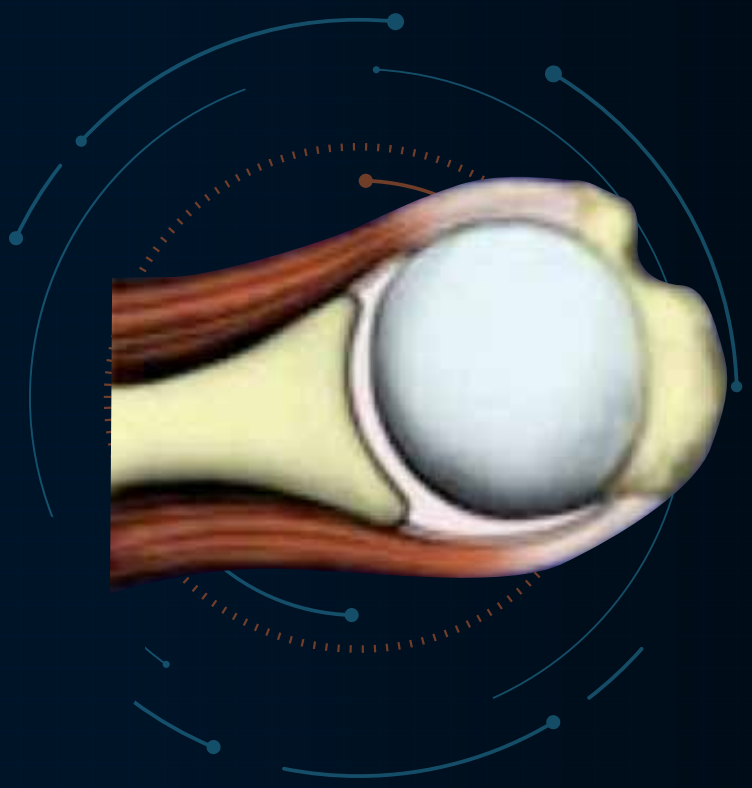

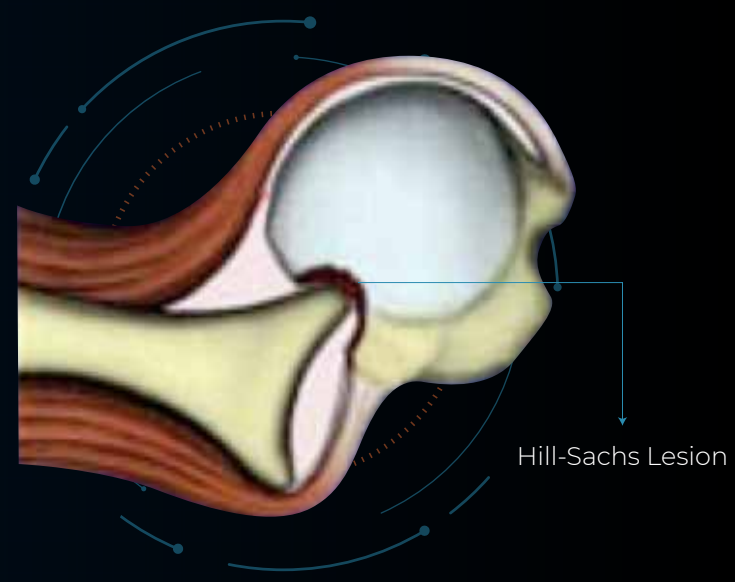

POSTERIOR INSTABILITY

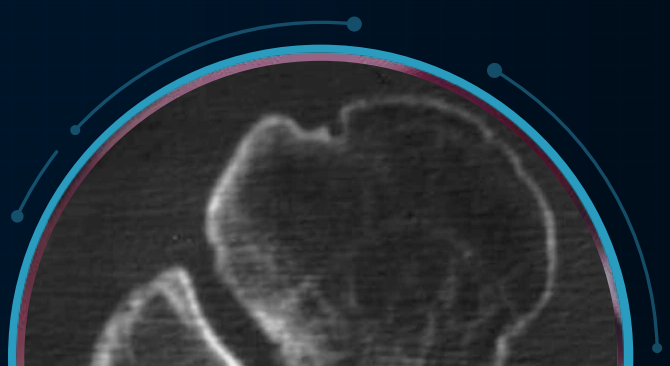

Associated with force applied to arm in a forward elevated adducted position such as with bench pressing, or when an offensive lineman gets jammed and with seizures.

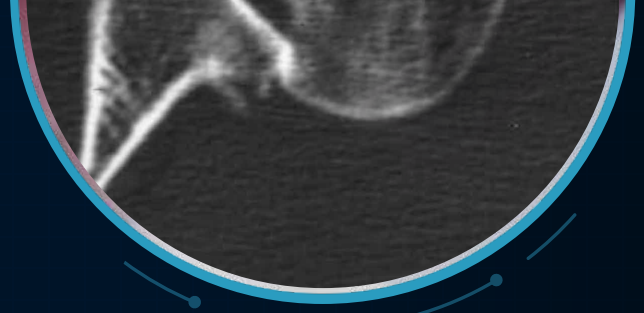

- Can have **posterior labral tear**, **posterior glenoid fractures** and **reverse Hill Sachs lesion**

TREATMENT OF TRAUMATIC INSTABILITY

Arthroscopic Suture Capsulorrhaphy

- Has a **94% success** rate in patients without a significant bony injury
- **Labrum** is repaired using suture anchors and capsule is selectively tightened

Suture Anchor

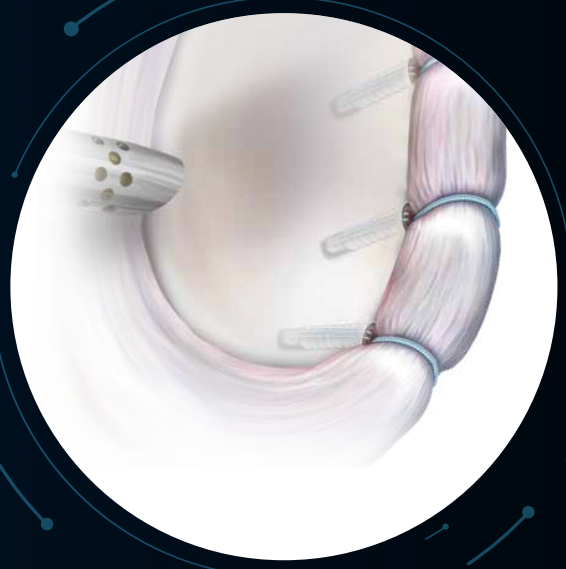

Anterior Labral Repair

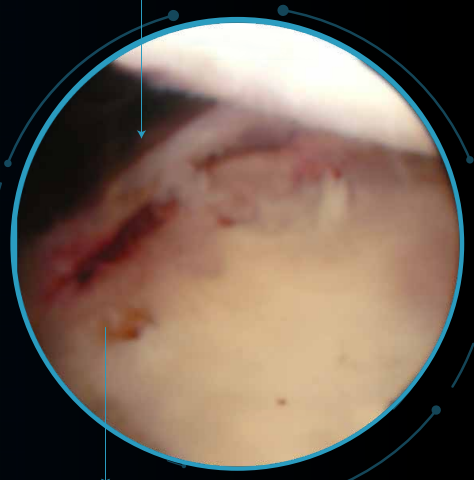

POSTOPERATIVE REHABILITATION AFTER SHOULDER STABILIZATION

Weeks 1-4

- No external rotation greater than 30 degrees and stress return of forward elevation
- No abduction/external rotation Sling for the first 4 weeks
- May do pendulum exercises
- Isometric rotator cuff and scapular stabilizer strengthening

Weeks 4-8

- Restore full active forward elevation
- No abduction external rotation stretching
- May do scapular stabilizer strengthening and IR/ER rotator cuff strengthening

Weeks 8-12

- No abduction external rotation stretching
- Continue internal and external rotator cu strengthening and scapular stabilizer strengthening.
- No strengthening exercises above 90 degrees of forward elevation
- May start supraspinatus strengthening if scapulohumeral rhythm restored

4+ Months

- May start throwing rehabilitation
- May return to sports except high collision sports such as football, wrestling, basketball and rugby which is started at 6 months
- May start bench pressing but no heavy bench pressing until 6 months

Risks of Surgery

include stiffness, recurrent instability and prolonged rehabilitation

Risk of recurrent dislocation

includes osteoarthritis

SHOULDER INSTABILITY